
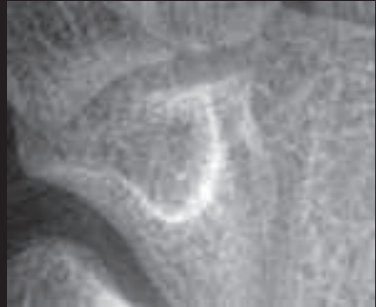








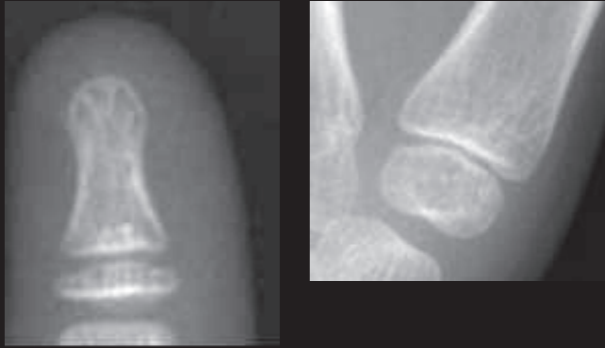






# HSS Bone Age

## Male Ages (in Years)

<p><b>12.5</b></p> <p>Appearance of hook of hamate</p>	<p><b>13</b></p> <p>Appearance of MP thumb sesamoid</p>	<p><b>13.5</b></p> <p>Proximal aspect of radial epiphysis has extended to meet the maximum width of the distal metaphysis, but neither radial-sided nor ulnar-sided capping is completed</p>	<p><b>14</b></p> <p>Completion of capping of distal radius epiphysis</p>	<p><b>15</b></p> <p>Closure of thumb distal phalanx physis</p>	<p><b>15.5</b></p> <p>Closure of index finger distal phalanx physis and Closure of thumb metacarpel</p>	<p><b>16</b></p> <p>Closure index finger proximal phalanx physis</p>
<p><b>Before 12.5</b></p>  <p><b>↓</b></p> <p><b>12.5</b></p> 	<p><b>Before 13</b></p>  <p><b>↓</b></p> <p><b>13</b></p> 	<p><b>Before 13.5</b></p>  <p><b>↓</b></p> <p><b>13.5</b></p> 	<p><b>Before 14</b></p>  <p><b>↓</b></p> <p><b>14</b></p> 	<p><b>Before 15</b></p>  <p><b>↓</b></p> <p><b>15</b></p> 	<p><b>Before 15.5</b></p>  <p><b>↓</b></p> <p><b>15.5</b></p> 	<p><b>Before 16</b></p>  <p><b>↓</b></p> <p><b>16</b></p> 